

**Original Article**

**EVALUATION OF EXCISIONAL AND INCISIONAL WOUND HEALING ACTIVITY OF ELECTROHOMEOPATHIC DRUG (SPAGYRIC ESSENCE) GREEN ELECTRICITY IN RATS**

**PRASANT KUMAR SABAT\*, SWETA PRIYADARSINI PRADHAN, RANDEEP PATRO**

School of Pharmaceutical Sciences, Siksha 'O' Anusandhan (Deemed to be) University, Kalinga Nagar, Bhubaneswar, 751003, Odisha, India  
Email: pksabat27@gmail.com

Received: 08 Jun 2020, Revised and Accepted: 26 Aug 2020

**ABSTRACT**

**Objective:** The current research is an attempt to evaluate the wound healing activity of Electrohomeopathic drug Green electricity (GE) in Wistar rats. No data have been reported till date on the wound healing effect of GE. Hence the present research focuses on the scientific investigation of the wound healing activity of GE in rats.

**Methods:** Excision and incision wounds were inflicted upon albino rats. In the excision wound model, the wound contraction, Scar residue, area and time of complete epithelization were measured subsequently on day 0, 3,6,9,12,15, 18 and 21 after inflicting the wound. Wound contraction was calculated as a percentage change in the initial wound size. In the incision wound model, the tensile strength was measured on the 10<sup>th</sup> post wounding day.

**Results:** It was noted that the effect produced by the GE Showed significant wound healing ( $p < 0.01$ ) in all wound models when compared to the control group. In the case of the excision model, GE statistically increases the wound contraction rate and in the case of the incision model GE showed high tensile strength as compared to the control group. In both cases the epithelization period was significantly decreased as compared to control. Almost 100% wound protection was achieved by GE in 21 d as compared to control.

**Conclusion:** GE (ointment) showed significant wound healing activity ( $p < 0.01$ ) in both the excised wound model and incision wound model in rats.

**Keywords:** Electrohomeopathy, Green electricity, Excision, Incision

© 2020 The Authors. Published by Innovare Academic Sciences Pvt Ltd. This is an open access article under the CC BY license (<http://creativecommons.org/licenses/by/4.0/>)  
DOI: <http://dx.doi.org/10.22159/ijpps.2020v12i10.38674>. Journal homepage: <https://innovareacademics.in/journals/index.php/ijpps>.

**INTRODUCTION**

Electrohomeopathy an alternate medical system introduced by Dr. Count Seizer Matti of Italy in 1865. Later Krauss 1914, N. L. Sinha 1920 Gidden 1951, Whitmee 1956, and many others successfully enriched the data by this method and created it commonly. Since then it is comprehensively practiced in many countries by the electrohomeopathic practitioners [1].

GE is an electrohomeopathic drug (Spagyric essence) prepared by cohobation method from different parts of plants such as *Althea officinalis* (Simaroubaceae), *Evum lens* (Fabaceae), *Populus alba* (Salicaceae), *Populus tremuloides* (Salicaceae), *Conium maculatum* (Apiaceae), *Sambucus nigra* (Adoxaceae), *Hamamelis virginiana* (Hamamelidaceae), *Phytolacca decandra* (Phytolaccaceae). Then the spagyric essences were mixed in a specified ratio. Traditionally GE is extensively used by the practitioners to heal the wounds of different kinds. However, literature survey does not reveal any scientific report on wound healing activity of GE. So the present study is an attempt to evaluate the wound healing efficacy of GE.

Wound healing is a characteristic therapeutic reaction to tissue injury. Healing is the process of intricate cellular events, which is a systemic process, generally explained in terms of four traditional stages, that is a) hemostasis, 2) inflammation, 3) proliferation, 4) maturation [2]. The factors which influence wound healing are local infection by tissue organization, poor blood supply to the affected part, exposure to ionizing radiation and the inclusion of foreign bodies. But GE overcomes all possible hurdles and shows immense potential in the healing of wounds.

The wounds arise due to physical and chemical injury or microbial infection [3]. To avoid septicity or any further complicity, any sort of wound healing formulation, either topically or orally or injectable formulation has to be given to the victim. As the electrohomeopathic topical formulation is safe, cheap and highly effective and it is used widely by local practitioners, the research is quite rational to confirm the folkloric claim of the wound healing ability of GE topically.

**MATERIALS AND METHODS**

**Preparation of ointment**

Ointment base was prepared by mixing the ingredients (wool fat 5g, hard paraffin 5g, cetostearyl alcohol 5g, soft paraffin 85g) as per British Pharmacopeia (1980) in a beaker at 65 °C on a water bath. After cooling, the mixture was homogenized by a homogenizer at 1500rpm for 10-15 min [4]. The ointment base was mixed with the GE (5%w/w) by trituration with using a mortar and pestle in order to get a homogeneous ointment preparation. At every fifth-day interval, fresh drug formulations were prepared. Wool fat, cetostearyl alcohol, soft paraffin and hard paraffin are from Burgoyne Burbidges and Co Company and obtained from Pharmaceutics department, SPS, SOA University, Bhubaneswar, Odisha. Povidine ointment was purchased from a local chemist.

**Preparation of animals for *in vivo* wound healing study**

Wistar albino rats of either sex weighing between 180-200g were obtained from the departmental animal house of SPS, SOA University, Bhubaneswar, Odisha. The animals were kept under controlled environmental conditions at 25±2°C temperature and 45-55% relative humidity with natural light cycle and allowed to take food (Standard Pellet Dier, Hindustan Lever Ltd, India) and water. They were acclimated for one week before the beginning of the experiment [5].

**Treatment protocol**

The Wistar rats were separated into three groups of six rats each. The current research conducted was approved by the institutional animal ethical committee of School of Pharmaceutical Sciences, SOA University, Odisha, India. (Registration No.1171/C/08/CPCSEA)

Group I was served as control and treated with a simple ointment base topically

Group II was served as standard treated with 5% Povidine iodine ointment topically

Group III was served as test treated with Elecrohomeopathic drug GE ointment topically

#### Wound healing activity in excision wound model

Excision of wounds was made as described by Smitarani and K. Remya (2017) [6]. Anesthetic ether is used to anesthetize the animals and thereafter Animals were placed on a dissection table in their natural position. The dorsal thoracic region is sterilized with ethanol and then a square wound (1.5 cm width x 0.2 cm depth) was made in the above region. The Group I animals was topically treated with a simple ointment base. The Group II animals were topically treated with povidine iodine ointment. The Group III animals were treated with 5% WE ointment topically once a day till the epithelization was complete. Just after wounding all the rats were kept in individual, clean cages to avoid damage to the wound and prevent infection. Food and water were given after 2 to 3 h after the day of operation. No systematic or oral antibiotic was given after a postoperative period. The animals were inspected daily for any evidence of infection. The day of wounding was referred to as day-0. The wound contraction, Scar residue, area and time of complete epithelization were also measured subsequently on day 0, 3,6,9,12,15, 18 and 21. The wound contraction was studied by tracing the raw wound area on graph paper. The wound closure percentage (i.e. the percentage of wound protection) and the epithelization period were recorded [7].

#### Wound contraction rate

The wound contraction rate was measured at every 2 d interval. It is the percentage reduction of wound size. It can also be treated as a percentage of wound protection. By using a transparency paper and a suitable marker, at a specified interval, the decrease in size of wounds was monitored and accordingly, the percentage of wound closure is accessed, which indicates the formation of fresh epithelial tissue to heal the wound. Wound contraction was expressed as a reduction in the percentage of the original wound size [8].

$$\% \text{ of wound contraction} = \frac{\text{Initial area of wound on day 0} - \text{Area of wound on N}^{\text{th}} \text{ day}}{\text{Wound area on day 0}} \times 100$$

#### Epithelization time

The Appearance of eschar without any raw wound area was treated so that the wound is completely healed. The number of days required for the appearance of eschar without any leftover raw wound was calculated as epithelization period [9].

#### Wound healing activity in the incision model

The animals were anesthetized with ether. The animals were kept on the operating table in the common position. One paravertebral straight incision of six centimeters was made on either side of the vertebral segment with the help of a scalpel blade. The wound was cleaned with 70% alcohol-soaked cotton balls. The animals were kept in independent cages. The Group I animals was topically treated with a simple ointment base, the Group II animals were topically treated with povidine iodine ointment and the Group III animals were treated with 5% WE ointment applied topically daily for ten days. On the 9<sup>th</sup> day of post wounding, sutures were removed. On the 10<sup>th</sup> day of post wounding the tensile strength was

measured. The tensile strength is the strength of a healing wound which is estimated by the amount of force required to disrupt it.

#### Determination of tensile strength

The wound healing and restoration of tissue strength are the outcome of the repair process. The tensile strength or breaking strength is the most crucial phase in the above process. The collagen and elastic fiber networks of the dermis are responsible for the mechanical properties of skin. The least force required to break the incision apart, which shows the degree of healing, strength of wound tissue and the efficacy of the healing process [10].

On the 9<sup>th</sup> postoperative day, the skin sutures are removed. On 10<sup>th</sup> day one side of the wound was applied with gradually increasing weight while the other was fixed. The weight that totally separated the wound from the incision line is considered to be the breaking strength or tensile strength. The mean breaking strength on the two para-vertebral incisions on both sides of the animals was taken as the measure of the breaking strength of the individual animal [11, 12].

#### Statistical analysis

All results are expressed as mean±SD. The statistical significance was evaluated by one-way and two-way ANOVA followed by Bonferroni multiple comparison tests using Graph Pad Prism 8.4.2 software [13, 14].

### RESULTS

#### Wound contraction and epithelization time (excision wound)

The progressive decrease of the wound area of different groups of animals over 21 d by GE ointment is presented in fig. 1.

If wound contraction is concerned, 100% wound contraction is achieved in 21 d in the test group (treated with WE) and ultimately faster as well as complete healing is achieved, whereas the standard group (treated with povidine iodine ointment.) also took 21 d for the same achievement. However, the control group (treated with a simple ointment base only) did not achieve complete healing within specified days. This proves GE showed highly significant wound healing activity ( $p < 0.05$ ) as compared to control group animals (fig. 2).

If the epithelization rate is concerned, on the 18<sup>th</sup> post wounding day the WE ointment treated animals showed a remarkable reduction in the wound area (95.88%) with fast epithelization rate. However, the complete epithelization was also observed in the animals treated with standard drugs (5% w/w Povidine-iodine). Whereas the lower rate of wound healing with the highest epithelization time (21 d) was observed in the control group.

#### Tensile strength (incision wound)

The tensile strength of healing skin of different groups like control, test and standard was compared and it was found that the test group was substantially higher than other groups (fig. 3). Thus in the incision wound model, there is a significant increase in skin tensile strength ( $p < 0.05$ ) by GE and standard as compared to control group animals (table 1). All the recorded observations confirmed that WE ointment possesses excellent wound healing properties.

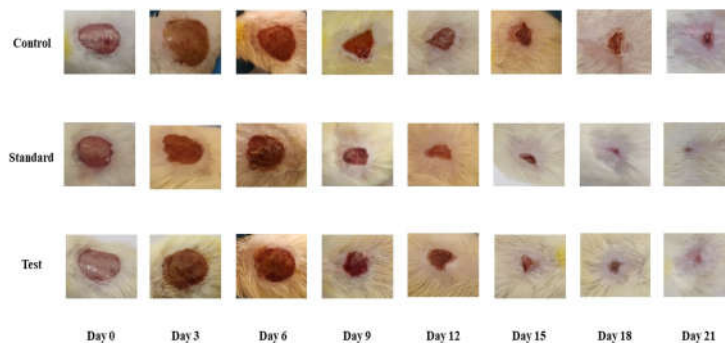


Fig. 1: Wound contraction on post wounding days

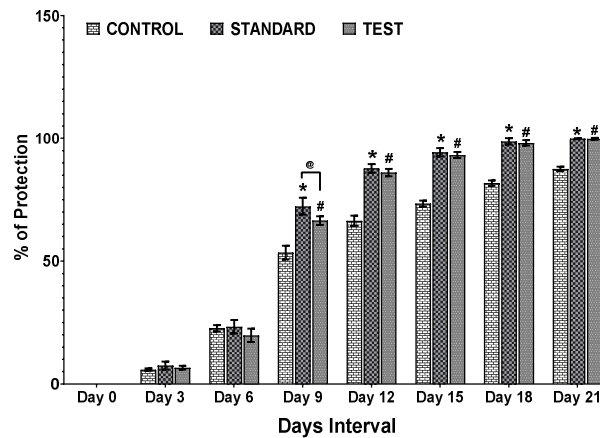


Fig. 2: Effect of topical ointment of GE application and its constituents expressed as a percentage of protection. Values are expressed as mean±SD, n=6. \* $p < 0.05$  denotes significant difference in control versus standard, @ $p < 0.05$  denotes a significant difference in standard versus test and # $p < 0.05$  denotes a significant difference between control and test ointments

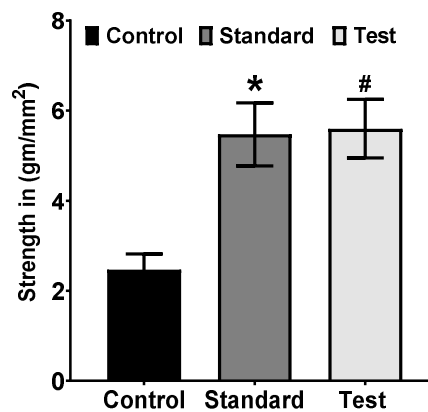


Fig. 3: Effect of topical ointment of GE application and its constituents expressed as a percentage of protection. Values are expressed as mean±SD, n=6. \* $p < 0.05$  denotes a significant difference in control versus standard and # $p < 0.05$  denotes a significant difference between control and test ointments

Table 1: Effect of GE on tensile strength of the incised wound

Tensile strength day 10							
Group	Treatment	Bodyweight	Marking	Gram used	In g/mm <sup>2</sup>	Mean	Standard deviation
I	Control	177	H	165	2.75	5.597222222	0.651017722
		151	B	115	1.916666667		
		153	T	134	2.233333333		
		184	H+B	147	2.45		
		179	H+T	171	2.85		
II	Standard	162	UM	157	2.616666667	2.469444444	0.348395795
		165	H	289	4.816666667		
		198	B	314	5.233333333		
		161	T	357	5.95		
		183	H+B	362	6.033333333		
III	Test	197	H+T	375	6.25	5.475	0.7006941
		158	UM	274	4.566666667		
		158	H	320	5.333333333		
		151	B	297	4.95		
		176	T	354	5.9		
		164	H+B	382	6.366666667		
		149	H+T	372	6.2		
		152	UM	290	4.833333333		

Values are expressed as mean±SD, n=6. All the groups were compared with control. The statistical significance was evaluated by one-way and two-way ANOVA followed by Bonferroni multiple comparison tests.

## DISCUSSION

Though synthetic drugs are used in a large-scale, they are found to be high cost, toxic and may produce any local allergy on prolonged use. The herbal based drug may prove an alternate due to its low cost and safe character. Therefore the use of herbal-based ointment for wound healing is quite rational. A systemic application was made to observe the efficacy of plants against wounds so as to use them as an herbal wound healing agent [15].

When a tissue is damaged and the wound is formed, the restoration activity in its normal state is a complex and dynamic phenomenon. Many factors like host's health, damage extent and tissue type influences the healing and repairing ability. Hemostatis, re-epithelization, granulation, remodeling of the extracellular matrix and scar formation are characteristic of the healing process [16]. The aim of the present work is to verify the use of WE for wound healing and the ability of wound healing by the GE ointment.

As a single method is not sufficient to explain the various components of the wound healing process [17]. The present work focused to evaluate the process of wound healing in different wound models. Herbal based ointment consists of different medicinal plants used in wound healing and has been accounted for to be successful in wound care, advancing injury mending, relieving pain, and scarring of the patient [18].

The rapid epithelization in a shorter time is responsible for shrinkage of wounds [19]. This has been revealed *in vivo* study that animals treated with WE ointment have a high shrinkage of wound area in a shorter time. The tensile strength depends upon the level of collagen and the formation of stable intra and intermolecular cross linking. An increase in tensile strength explained the probable the increased synthesis of collagen fibers liable for cross-linkage bring about more, resulting in greater tensile strength. The GE treated animals showed high tensile strength because of increased synthesis of collagen fibers and thus increases in cross-linkage.

The increase in granulation tissue weight animals suggests high protein content and improved collagen development because of increased cross linking of collagen fibers. The granulation tissue formed in the proliferative phase comprises fibroblast, collagen, inflammatory cells and small blood vessels. Wound contraction is a fibroblast-dependant strategy, including the deposition and maturation of collagens. The WE treated animals indicated the tensile strength of granulation tissue expands proliferation within collagen deposition and maturation.

However the healing process like coagulation, inflammation, macrophage, fibroplasias, collagenation, contraction and epithelization are personally interlinked. On the way, treatment could impact the healing process by mediating at least one phase of healing. Here, animals treated with WE ointment remarkably enhance in collagen synthesis, which is the predominant extracellular protein in the granulation tissue of wounds. Thus the wound healing activity of the WE ointment is most likely because of the initiation of different elements related to the wound healing process and inflammatory pathways. This is maybe because of the capability of plant constituents in GE.

## CONCLUSION

Electrohomeopathic drug GE showed a significant wound healing effect in both the excised wound model and incision wound model rats. As it is affordable, safe and quite effective as compared to synthetic topical antibacterial agents, it can be used as an alternative for all kinds of wound healing in case of minor injury or during surgical dressing purposes. However, further study is needed to find out the Phytoconstituents responsible for the observed effect.

## ACKNOWLEDGEMENT

The authors are thankful to Dr. Parsuram Khatua (ERDCO) and Dr. Manoj Mahala (Electrohomeopathic practitioner) for their valuable suggestions during the study.

## FUNDING

Nil

## AUTHORS CONTRIBUTIONS

P. K. Sabat made a substantial contribution to conception and designs the experiment and wrote the manuscript and revised manuscript, S. Pradhan performed the experiment, and R. Patro analysed the data.

## CONFLICT OF INTERESTS

The author declares no conflict of interest.

## REFERENCES

1. Sureshbabu P, Siddalingamurthy E, Sashidhara NL, Sooryanarayananarao B, Bhavya DC. A review on electrohomeopathic medicinal practice: origin, principles, medicinal plants used and its current status in India. *Euro J Med Plants* 2020;8:31-47.
2. Sudha Bhargavi CH, Swami V, Bilal S, Ushasri S, Kumar R. Wound healing activity of alcoholic extract of *Solanum erianthum* D. Don in excision and incision method. *Int J Res Ayur Pharm* 2013;4:130-5.
3. Biswas TK, Mukherjee B. Plant medicines of Indian origin for wound healing activity, a review. *Int J Lower Extrem Wounds* 2003;2:25.
4. *British Pharmacopia*; 1980. p. 1096.
5. Mohanty A, Pal A, Sahu PK. Wound healing activity of *Baringtonia acutangula* fruit extract. *Asian J Pharm Clin Res* 2016;9:236-8.
6. Smitarani RK, Remya K, Bency BT, Shebina PR, Azeem AK, Sajeev VK. Investigation on the wound healing activity of aqueous extract of *Emilia sonchifolia* (L.) Dc. *Int J Herb Med* 2017;5:34-9.
7. Morton JJP, Malone MH. Evaluation of vulnerary activity by an open wound procedure in rats. *Arch Int Pharmacodyn Ther* 1972;196:117-26.
8. Ghosh S, Samanta A, Mandal NB, Banerjee S. Evaluation of the wound healing activity of methanol extract of *Pedilanthus tithymaloids* (L.) poit leaf and its isolated active constituents in topical formulation. *J Ethnopharmacol* 2012;142:714-22.
9. Chitra P, Sajithal GB, Chandrakasan G. Influence of *Aloe vera* on healing of dermal wounds in diabetic rats. *J Ethnopharmacol* 1998;59:195-201.
10. Shetty S, Udupa S, Udupa L. Evaluation of antioxidant and wound healing effect of alcoholic and aqueous extract of *Ocimum sanctum* linn in rats. *eCAM* 2008;5:95-101.
11. Garg VK, Paliwal SK. Wound healing activity of ethanolic and aqous extracts of *Ficus benghalensis*. *J Adv Pharm Technol* 2011;2:110-4.
12. Lodhi S, Vadnere G. Relevance and perspectives of experimental wound models in wound healing research. *Asian J Pharm Clin Res* 2017;7:57-62.
13. Dwivedi D, Dwivedi M, Malviya S, Singh V. Evaluation of wound healing, anti-microbial and antioxidant potential of *Pongamia pinnata* in wistar rats. *J Trad Comple Med* 2017;7:79-85.
14. *Practical Pharmacology for the Pharmaceutical Sciences* by D. Michael Salmon. Edition; 2014.
15. Ravichandran V, Manivannan S. Wound healing potential of transdermal patches containing bioactive fraction from the bark of *Ficus racemosa*. *Int J Pharm Pharm Sci* 2015;7:326-32.
16. Mary B, Priya KS, Gnanamani A, Radhakrishnan N. Healing potential of *Datura alb* on burn wound in albino rats. *J Ethnopharmacol* 2002;83:193-9.
17. Shirwaikar A, Shenoy R, Udupa AL, Udupa SL, Shetty S. Wound healing property of ethanolic extract of leaves of *Hyptis suaveolens* with supportive role of antioxidant enzymes. *Indian J Exp Biol* 2003;41:238-41.
18. Odimegwu DC, Ibezim EC, Adikwu Mu, Boniface JAE, Ogbu HI, Esimone CO. Bioassay-tracked temperature-stress-induced chemical degradation of bio-active wound healing, antibacterial extract of *Dissotis theifolia* stem dispersed in a pharmaceutical cream and ointment. *Int J App Res in Nat Prod* 2011;1:20-8.
19. Priya KS, Arumugam G, Rathinam B, Wellis A, Babu M. *Celosa argentea* leaf extract improves wound healing in a rat burn wound model. *Wound Rep Regen* 2004;12:618-25.